

## Masculinisation of the Middle and Lower Third of the Face using Endopeel Techniques

Alain Tenenbaum<sup>1</sup>, Mauro Tiziani<sup>2</sup>, Ercin Ozüntürk<sup>3</sup>

<sup>1</sup>ALAIN TENENBAUM,

<sup>2</sup>MAURO TIZIANI

<sup>3</sup>ERCIN OZUENTUERK

### Introduction & Objectives

Not surgical masculinization technics are increasing exponentially in the last decade.

New options requested by these patients are the ones with these following criteris:

NOT SURGICAL

WITHOUT DOWNTIME

WITH IMMEDIATE EFFECT

SCARLESS

WITHOUT OR WITH REVERSIBLE SHORT DURATION SIDE EFFECTS

WITH A REASONABLE PRICE

WITH LESS CONTRA-INDICATIONS.

Endopeel techniques are among these new options. The objectives are to get isovolumetric 3D myoplasty (reshaping the size, the projection and the tension of the chosen muscles for an aesthetic area) without paralysis and without adding volume.

### Materials & Methods

Endopeel Techniques are used using a chemical patented formula by SC and IM injections, using vectors and tensors marked with analogy to visco elastic elastomers deformation. Specific Oily phenic acid is used.

### Results

Results show mostly a lifting, tightening, and projecting effect with better skin quality or a 3 D deformation of viscoelastic muscular elastomeres. Results can be seen after 1/2 hour and have an average duration of 6 months

### Conclusions


Endopeel or Chemical Myoplasty and Myopexy for masculinization is a new concept quick, easy to realize, not surgical, with immediate effect, with affordable prices, and taking care that each patient is different, following the fashion, the ethny, the life standard. The MD is like a tailor reshaping the face following science and fashion. That s fashion medicine.

### Masculinisation of the Face in 30 Min

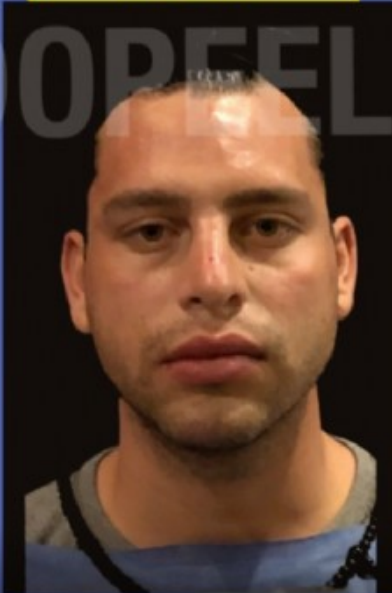
## Whole Face Masculinization

## Results after ½ hour

**BEFORE**



**AFTER**



Courtesy of Alain Tenenbaum

1. Wider Forehead
2. Overhanging horizontal brow
3. Prominent Supraorbital Ridge
4. Minimal Eyebrow Arch
5. Eyes appearing closer together
6. Acute naso frontal angle <90
7. Wider mouth, thinner upper lip
8. Squared Jaw
9. Acute naso labial angle
10. Rising branche of the mandible
11. Bone Cheek
12. Mandibular Angle
13. Naso labial furrow
14. Squared Chin

**the 3 authors in full face***the 3 authors in full face*

## Details

**Status** : In author: Saved draft  
**Presentation Type** : Oral Presentation  
**Abstract Category/Topic** : Research in D/V, Experimental D/V  
**Language** : English  
**Saved:** : 07.02.2021 22:19:51  
**Submit:** :

## Confidential to Author and Editor

**Presenter** : Alain Tenenbaum (drpeeling@bluewin.ch)

[Close](#)[Print](#)